






## SPECIAL REPORT

# The ILAE classification of seizures and the epilepsies: Modification for seizures in the neonate. Position paper by the ILAE Task Force on Neonatal Seizures

Ronit M. Pressler<sup>1,2</sup>  | Maria Roberta Cilio<sup>3</sup>  | Eli M. Mizrahi<sup>4</sup> | Solomon L. Moshé<sup>5,6</sup>  |  
Magda L. Nunes<sup>7</sup>  | Perrine Plouin<sup>8</sup> | Sampsa Vanhatalo<sup>9</sup> | Elissa Yozawitz<sup>5,6</sup>  |  
Linda S. de Vries<sup>10</sup> | Kollencheri Puthenveetil Vinayan<sup>11</sup> | Chahnez C. Triki<sup>12</sup> |  
Jo M. Wilmschurst<sup>13</sup>  | Hitoshi Yamamoto<sup>14</sup> | Sameer M. Zuberi<sup>15</sup>

<sup>1</sup>Clinical Neuroscience, UCL- Great Ormond Street Institute of Child Health, London, UK

<sup>2</sup>Department of Clinical Neurophysiology, Great Ormond Street Hospital for Children, NHS Foundation Trust, London, UK

<sup>3</sup>Division of Pediatric Neurology, Institute for Experimental and Clinical Research, Saint-Luc University Hospital, Université Catholique de Louvain, Brussels, Belgium

<sup>4</sup>Departments of Neurology and Pediatrics, Baylor College of Medicine, Houston, TX, USA

<sup>5</sup>Isabelle Rapin Division of Child Neurology, Saul R. Korey Department of Neurology, Albert Einstein College of Medicine and Montefiore Medical Center, Bronx, NY, USA

<sup>6</sup>Department of Pediatrics, Albert Einstein College of Medicine and Montefiore Medical Center, Bronx, NY, USA

<sup>7</sup>Pontificia Universidade Catolica do Rio Grande do Sul - PUCRS School of Medicine and the Brain Institute, Porto Alegre, RS, Brazil

<sup>8</sup>Department of Clinical Neurophysiology, Hospital Necker Enfants Malades, Paris, France

<sup>9</sup>Department of Clinical Neurophysiology and BABA center Children's Hospital, HUS Imaging, Neuroscience Center, Helsinki Institute of Life Science, Helsinki University Central Hospital and University of Helsinki, Helsinki, Finland

<sup>10</sup>Department of Neonatology, University Medical Center Utrecht, Utrecht University, Utrecht, The Netherlands

<sup>11</sup>Department of Pediatric Neurology, Amrita Institute of Medical Sciences, Cochin, Kerala, India

<sup>12</sup>Department of Child Neurology, Hedi Chaker Hospital, LR19ES15 Sfax University, Sfax, Tunisia

<sup>13</sup>Department of Paediatric Neurology, Red Cross War Memorial Children's Hospital, Neuroscience Institute, University of Cape Town, Cape Town, South Africa

<sup>14</sup>Department of Pediatrics, St. Marianna University School of Medicine, Kawasaki, Japan

<sup>15</sup>Paediatric Neurosciences Research Group, Royal Hospital for Children & Institute of Health & Wellbeing, University of Glasgow, Glasgow, UK

## Correspondence

Ronit M. Pressler, Department of Clinical Neurophysiology, Great Ormond Street Hospital for Children NHS Foundation Trust, London, WC1N 3JH, UK.  
Email: ronit.pressler@gosh.nhs.uk

## Abstract

Seizures are the most common neurological emergency in the neonatal period and in contrast to those in infancy and childhood, are often provoked seizures with an acute cause and may be electrographic-only. Hence, neonatal seizures may not fit easily into classification schemes for seizures and epilepsies primarily developed for older children and adults. A Neonatal Seizures Task Force was established by the International League Against Epilepsy (ILAE) to develop a modification of the 2017 ILAE Classification of Seizures and Epilepsies, relevant to neonates. The neonatal classification framework emphasizes the role of electroencephalography (EEG) in

the diagnosis of seizures in the neonate and includes a classification of seizure types relevant to this age group. The seizure type is determined by the predominant clinical feature. Many neonatal seizures are electrographic-only with no evident clinical features; therefore, these are included in the proposed classification. Clinical events without an EEG correlate are not included. Because seizures in the neonatal period have been shown to have a focal onset, a division into focal and generalized is unnecessary. Seizures can have a motor (automatisms, clonic, epileptic spasms, myoclonic, tonic), non-motor (autonomic, behavior arrest), or sequential presentation. The classification allows the user to choose the level of detail when classifying seizures in this age group.

#### KEY WORDS

classification, EEG, epilepsy, neonatal seizures, semiology

## 1 | DEFINITIONS

For the purpose of this report, the following definitions are used<sup>1,2</sup>:

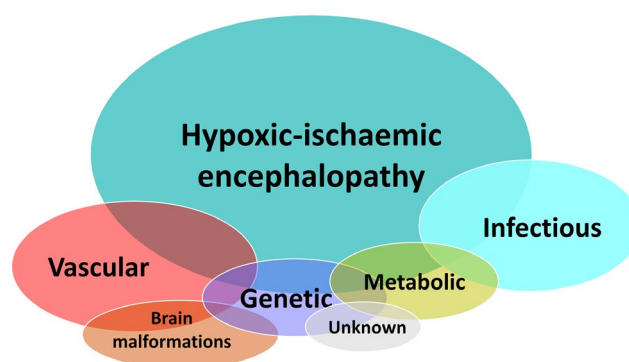
- Gestational age (GA): time elapsed between the first day of the last menstrual period and the day of delivery (completed weeks).
- Postmenstrual age (PMA): gestational age plus chronological age (in weeks).
- Preterm infant: born before GA of 37 weeks.
- Neonatal period: period from birth up to 44 weeks PMA.

## 2 | INTRODUCTION

Seizures are the most common neurological emergency in the neonatal period, occurring in 1–5 per 1000 live births.<sup>3–5</sup> The majority of neonatal seizures are provoked by an acute illness or brain insult with an underlying etiology either documented or suspected, that is, these are acute provoked seizures (previously also called acute symptomatic, although acute provoked is now the preferred term). They do not meet the criteria for the diagnosis of epilepsy, which is defined as meeting any of the following conditions: (a) at least two unprovoked seizures occurring >24 hours apart; (b) one unprovoked seizure and a probability of further seizures similar to the general recurrence risk after two unprovoked seizures; and (c) diagnosis of an epilepsy syndrome.<sup>6,7</sup> Epilepsy syndromes may present in the neonatal period and, with the increasing availability of genetic testing, expanding numbers of neonatal epilepsies with genetic and metabolic etiologies are recognized.<sup>5,8</sup> Although many causes can give rise to neonatal seizures, a relatively small number account for most seizures (Figure 1) including hypoxic-ischemic encephalopathy,

#### Key points

- The International League Against Epilepsy (ILAE) presents a new classification and framework for seizures in the neonatal period in line with 2017 ILAE classifications.
- It emphasizes the key role of electroencephalography (EEG) for the diagnosis of seizures in this age group.
- Seizures are considered focal at onset, and thus a division into focal and generalized is unnecessary.
- Seizures can occur with clinical manifestations or without clinical manifestations (electrographic-only).
- Descriptors are determined by the predominant clinical feature and divided into motor, non-motor, and sequential.



**FIGURE 1** Relative occurrences of common etiologies of neonatal seizures in term infants. Adapted from <sup>3–5,8,81,82</sup>

stroke or hemorrhage, infections, cortical malformations, errors of metabolism (acute and inborn), and genetic etiologies. Less common but important causes are neonatal drug withdrawal and birth-related head trauma.

Neonatal seizures have been categorized previously as clinical only, electroclinical, or electrographic-only.<sup>9,10</sup> A clinical-only seizure has been defined as a sudden paroxysm of abnormal clinical changes without a definite EEG association. Currently there is no evidence that these clinical-only events are epileptic in nature (see historical review below). An electro-clinical seizure features definite clinical signs simultaneously coupled with an electrographic seizure. An electrographic-only seizure refers to the presence of an electrographic seizure seen on EEG that is not associated with any evident clinical signs (synonyms: clinically silent or subclinical seizures). The term electrographic-only is preferred, as this depends on observational methods used and the seizure may not be truly subclinical.

The clinical diagnosis of neonatal seizures is difficult, particularly in critically ill infants, due to the multitude of epileptic and nonepileptic clinical manifestations within the intensive care setting.<sup>9,11</sup> In the study by Malone, 20 video clips of paroxysmal events in neonates were presented to 137 health professionals (mostly neonatologists and intensivists) with the aim of classifying movements as seizure or nonseizure.<sup>12</sup> The average of correctly identified events was 10 of 20. There was poor inter-observer agreement independent of observers' specialty. The immature state of the motor pathways<sup>13,14</sup> in term and preterm neonates may account for some of the difficulties in differentiating seizures from nonepileptic movements.<sup>15</sup> In selected populations, particularly in infants with hypoxic-ischemic encephalopathy (HIE), 50%–80% of seizures are electrographic-only and, as a result, the extent of the seizure burden may be greatly underestimated.<sup>8–11,16,17</sup> Seizure burden can be defined as ictal (or seizure) electrographic activity in a given period of EEG recording and expressed as summed electrographic seizure seconds.<sup>18</sup> Seizure burden should be differentiated from seizure frequency, which does not take duration of seizures into account. Treatment of seizures, particularly with phenobarbital, can result in the so-called “uncoupling” or “decoupling,” meaning electroclinical seizures become electrographic-only.<sup>9,10,17,19–21</sup> Although therapeutic hypothermia for HIE reduces the overall seizure burden, it can also increase electroclinical uncoupling of seizures.<sup>11</sup> There is evidence that electrographic-only seizure burden has an effect on neurological outcome comparable to that of electroclinical seizures.<sup>16,22–26</sup>

The American Clinical Neurophysiology Society has recently defined an electrographic neonatal seizure as “a sudden, abnormal EEG event, defined by a repetitive and evolving pattern with a minimum 2  $\mu$ V peak-to-peak voltage and duration of at least 10 seconds.” “Evolving” is defined as an unequivocal evolution in frequency, voltage, morphology,

or location,<sup>27</sup> for example, increasing amplitude and decreasing frequency of discharges over time. This definition does not require any evident clinical change.

### 3 | HISTORICAL REVIEW

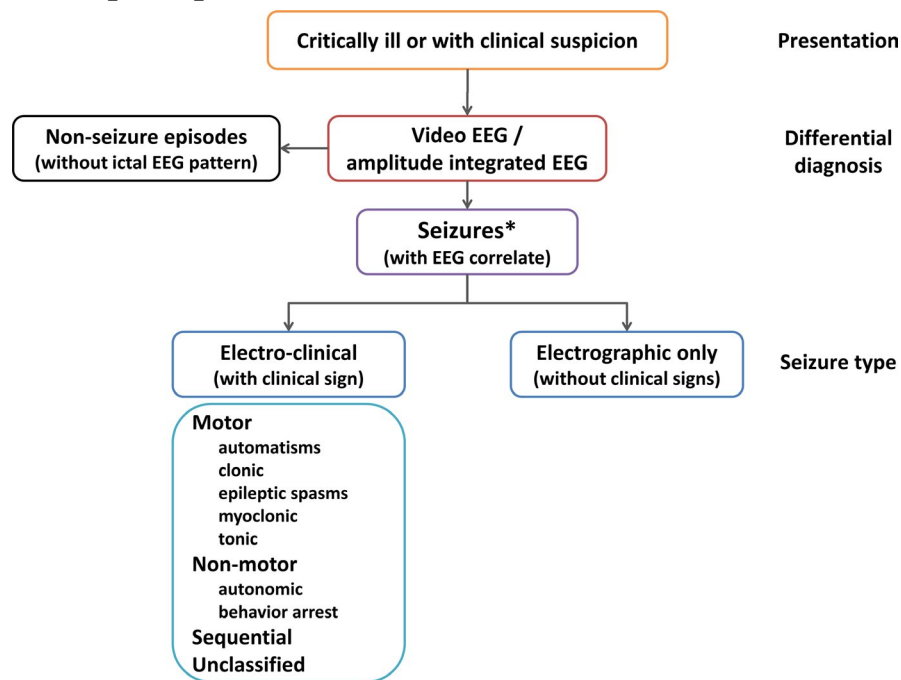
Historical efforts to characterize and classify neonatal seizures have been directed toward emphasizing how they differ from those of older children and adults. In this report, our aim is to use terminology consistent with the 2017 ILAE Classification of Seizures and the Epilepsies.<sup>7,28</sup>

Studies in the 1950s and early 1960s focused on motor and behavioral changes, were based on direct observation with or without EEG recordings, and included focal clonic and generalized tonic seizures,<sup>29–31</sup> and later also myoclonus.<sup>32</sup>

Early investigators recognized autonomic nervous system changes including variation in respiratory rate, vasomotor changes, salivation, heart rate, and blood pressure as seizure manifestations.<sup>33</sup> Polymorphic and atypical clinical events were described, the latter including staring, sudden awakening and alerting, eye deviation, eye blinking, nystagmus, chewing, and limb movements such as swimming, rowing, and pedaling,<sup>34</sup> classified as “anarchic,”<sup>30</sup> “minimal”<sup>35</sup> or “subtle.”<sup>36</sup> These findings resulted in the classification proposed by Volpe, which included: multifocal clonic, focal clonic, tonic, myoclonic, and subtle seizures.<sup>36,37</sup>

Correlating contemporaneous visual analysis of clinical seizures as well as electroencephalographic and polygraphic measures, Watanabe and colleagues recognized a wide range of motor, behavioral, and autonomic signs and provided detailed electroclinical correlations. Using video-EEG recordings, Mizrahi and Kellaway also documented electroclinical correlations and noted that many clinical events previously reported as seizures presumed to be of epileptic origin were in fact nonepileptic.<sup>9</sup> Events such as generalized tonic episodes and so-called subtle seizures, both of which occur without EEG correlate, could be provoked by stimulation and suppressed by restraint. This led to a reconsideration of the classification of neonatal seizures based on pathophysiology (epileptic vs nonepileptic); electroclinical relationships (electroclinical, clinical only, electrical only); or behavioral (focal clonic, focal tonic, myoclonic, spasms, generalized tonic, motor automatisms—each with additional modifiers to suggest whether they were considered to be of epileptic or nonepileptic origin). The term motor automatisms included ocular movements, oral-buccal-lingual movements, and “progression movements of the limbs” (pedaling, swimming, rowing).<sup>9</sup>

With the advent of prolonged bedside electrographic monitoring in the neonatal intensive care unit (NICU), it has been increasingly recognized that electrographic-only seizures without clinical correlates are frequent, particularly in critically ill neonates. As a result, the definition of neonatal



**FIGURE 2** Diagnostic framework of seizures in the neonatal period including classification of seizures. Adapted from 2017 ILAE seizure classification<sup>7</sup> Neonates present with discrete events suspected to be epileptic seizures or are critically ill (often ventilated, sedated, and treated with muscle relaxants in intensive care). \*If no EEG available refer to global alignment of immunization safety assessment in pregnancy levels of diagnostic certainty (Figure 5)

seizures has been reconsidered, now with a focus on the electrographic basis of the events, either with or without clinical manifestations.<sup>38</sup>

The 2017 ILAE Position Papers on Classification of Seizure Types and the Epilepsies presented a framework for classification including seizure types, epilepsy types, and syndromes.<sup>7,28</sup> A seizure is currently defined as a transient occurrence of signs and/or symptoms due to abnormal excessive or synchronous neuronal activity in the brain.<sup>6</sup> However, a seizure does not necessarily mean that a person has epilepsy. It is of note that electrographic-only seizures are not included in this definition. Seizure semiology is the description of signs and symptoms associated with an ictal event and is valuable in localizing the epileptogenic zone. In the neonate, the development within the limbic system with its connections to midbrain and brainstem is more advanced than the cerebral cortical organization, which may, in part, account for some differences in neonatal seizure semiology compared to that in older children.<sup>39</sup>

The ILAE Commission on Classification & Terminology recognized that seizures in the neonate require special considerations and therefore a Neonatal Task Force was established with the aim of integrating seizures and epilepsies in this age group into the 2017 ILAE Classification.

## 4 | METHODS

The goal of the task force was to develop a classification of seizures in neonates that can fulfil the following criteria:

- Integrate into the 2017 ILAE Classifications.

- Be based on electroclinical phenotype.
- Emphasize the key role of EEG in the diagnosis of neonatal seizures.
- Have implications for management and treatment of events.
- Be acceptable to neonatologists, pediatricians, epileptologists, neurophysiologists, and neurologists.
- Be applicable in all healthcare settings.

The task force followed the process for a Position Paper outlined by the ILAE (<https://www.ilae.org/files/dmfile/Process-of-Publishing-ILAE-Commission-and-Task-Force-Reports-25-Jan-2020.pdf>). This process includes the appointment of a task force (group of experts selected by the League), which produces an initial proposal, posting of this proposal on the ILAE website, soliciting comments, and criticism by all stakeholders (public consultation), and finally appointing a second expert panel to review and incorporate the public comments as well as the peer review by *Epilepsia*.

During the 5-month public consultation, we received comments from individuals as well as learned bodies and interested groups, all of which were reviewed by the second Task Force (see Report of the second neonatal seizure Task Force, Appendix S1). Most of the comments and criticisms were constructive and provided invaluable feedback, which informed the content of the Position Paper.

## 5 | CLASSIFICATION

Figure 2 depicts the diagnostic framework for seizures in the neonatal period, which includes the classification of seizures.

**TABLE 1** Integration with the 2017 ILAE Classification of Seizures and considerations for neonates.

Type	Description <sup>6,7</sup>	Special considerations	Clinical context of seizure type	Source
Automatisms	A more or less coordinated motor activity usually occurring when cognition is impaired. This often resembles a voluntary movement and may consist of an inappropriate continuation of preictal motor activity.	Typically oral in neonates. Behavior in term and preterm infants may mimic ictal automatisms, thus EEG / aEEG mandatory.	Seen in HIE and preterm infants. Often part of sequential seizures.	9,83,84
Clonic	Jerking, either symmetric or asymmetric, that is regularly repetitive and involves the same muscle groups.	Seizure type, which is more reliably diagnosed clinically.	Typical seizure type in neonatal stroke or cerebral hemorrhage. May be seen in HIE.	9,12,85–87
Epileptic spasms	A sudden flexion, extension, or mixed extension–flexion of predominantly proximal and truncal muscles that is usually more sustained than a myoclonic movement but not as sustained as a tonic seizure. Limited forms may occur: Grimacing, head nodding, or subtle eye movements.	Brief in neonates, thus may be difficult to differentiate from myoclonic seizures without EMG channel. May occur in clusters.	Rare. May be seen in inborn errors of metabolism or early-infantile DEE.	53,88–96
Myoclonic	A sudden, brief (<100 msec) involuntary single or multiple contraction(s) of muscles(s) or muscle groups of variable topography (axial, proximal limb, distal).	Clinically difficult to differentiate from non-epileptic myoclonus, requires EEG, ideally with EMG channels.	Typical seizure type in inborn errors of metabolism and preterm infants. May also be seen in early-infantile DEE.	88,90,91,93,94,97
Tonic	A sustained increase in muscle contraction lasting a few seconds to minutes.	Focal, unilateral or bilateral asymmetric. Generalized tonic posturing not of epileptic origin.	Typical seizure type early-infantile DEE and genetic neonatal epilepsies.	57,62,88,91,96,98,99,101
Autonomic	A distinct alteration of autonomic nervous system function involving cardiovascular, pupillary, gastrointestinal, sudomotor, vasomotor, and thermoregulatory functions.	May involve respiration (apnea). EEG / aEEG mandatory.	Rare in isolation. Seen in intraventricular hemorrhage as well as temporal or occipital lobe lesions. Also described in early-infantile DEE.	9,53,99,102–104
Behavioral arrest	Arrest (pause) of activities, freezing, immobilization, as in behavior arrest seizure.	EEG / aEEG mandatory.	Rare as an isolated seizure type. More commonly seen as part of sequential seizure.	53,105
Sequential seizure	This term is used in the instruction manual for the ILAE 2017 operational classification of seizure types for events with a sequence of signs, symptoms, and EEG changes at different times. <sup>6</sup>	No predominant feature can be determined, instead the seizure presents with a variety of clinical signs. Several features typically occur in a sequence, often with changing lateralization within or between seizures.	Often seen in genetic epilepsies such as self-limited neonatal epilepsy or KCNQ2 encephalopathy.	54,58,62,83,98–100

(Continues)



TABLE 1 (Continued)

Type	Description <sup>6,7</sup>	Special considerations	Clinical context of seizure type	Source
Electrographic-only seizure	Subclinical, without clinical manifestation.	EEG / aEEG mandatory.	Often seen in preterm infants, HIE (particularly in those with basal ganglia/thalamus injury), critically ill and neonates undergoing cardiac surgery.	9,11,15,81,106–109
Unclassified seizure type	Due to inadequate information or unusual clinical features with inability to place in other categories.	EEG / aEEG mandatory.		

Abbreviations: aEEG, amplitude-integrated EEG; early infantile DEE, early infantile developmental and epileptic encephalopathy; EEG, electroencephalography; EMG, electromyography; HIE, hypoxic-ischemic encephalopathy; ILAE International League Against Epilepsy; msec, milliseconds.

## 5.1 | Presentation

Newborns may present with paroxysmal clinical events suspected to be seizures of epileptic origin; these include motor and non-motor phenomena. However, as mentioned earlier, many neonates will have mostly or exclusively electrographic-only seizures, which will only become apparent on EEG or amplitude-integrated EEG (aEEG, see below).

## 5.2 | Diagnosis/Differential diagnosis

In neonates, video-EEG recording is the gold standard for diagnosis.<sup>4,9,18,40–42</sup> However, it is recognized that many neonatal units have only limited or no access to EEG. Instead, many neonatologists use aEEG, which is a simplified bedside neurophysiology tool displaying one or more commonly two channels of EEG in a filtered and compressed manner.<sup>43,44</sup> In situations when and where full EEG is not readily available, aEEG may be used with co-registration of raw channels, although its limitations are well recognized.<sup>4,45</sup>

A proportion of seizures are electrographic-only, particularly in encephalopathic and critically ill patients.<sup>10,11,46</sup> In the neonate, the immaturity of the central nervous system may also contribute. Hence, electrographic-only seizures should be part of the classification. The initial stage of description of a neonatal seizure should specify whether a seizure is with (electroclinical) or without clinical signs (electrographic-only). Instances have been described where clinical seizures occur both with and without an associated rhythmic EEG discharge in a given patient; however, this is considered to be a rare occurrence and by definition implies that electrographic seizures (with or without clinical correlate) also occur in that given patient.<sup>19,21</sup> Therefore, only events with EEG correlate are included in this classification. Theoretically, focal seizures originating from subcortical cerebral areas such as the limbic and peri-limbic systems may be missed. However, this notion is not, at present, provable or disprovable. Studies have shown that the most of clinical-only events are not of epileptic origin<sup>9,15</sup> and that in epileptic seizures an electrographic ictal pattern will become apparent during more prolonged EEG monitoring.<sup>16,47</sup> Polygraphic video-EEG can help to evaluate any manifestations in question such as autonomic features or automatisms and decrease the risk of over-diagnosing of common nonseizure events as epileptic.<sup>9,15,48,49</sup>

## 5.3 | Seizure types

We used the definition of seizure type as suggested by Fisher and colleagues: a useful grouping of seizure characteristics

**TABLE 2** Descriptors of motor seizures in the neonatal period

Seizure type	Descriptors
Automatisms	Unilateral Bilateral asymmetric Bilateral symmetric
Clonic seizures	Focal Multifocal Bilateral
Epileptic spasms	Unilateral Bilateral asymmetric Bilateral symmetric
Myoclonic seizures	Focal Multifocal Bilateral asymmetric Bilateral symmetric
Tonic seizures	Focal Bilateral asymmetric Bilateral symmetric

for purposes of communication in clinical care, teaching, and research.<sup>7</sup>

The basic principles of the 2017 ILAE classification of seizure types<sup>7</sup> (see online Appendix S2) are based on the 1981 classification with the initial division of seizures into those of focal and generalized onset.<sup>50,51</sup> Newborns have been shown to have seizures with exclusively focal onset,<sup>38,52</sup> thus the initial division into focal and generalized is unnecessary. Nevertheless, in some rare conditions, seizures may rapidly engage bilaterally distributed networks such as spasms or myoclonic seizures, for example, in inborn errors of metabolism. Even in genetic early infantile developmental and epileptic encephalopathies, tonic seizures are initially focal or asymmetric in the neonatal period<sup>9,53</sup> and subsequently may become generalized in infancy. The second level in the 2017 ILAE classification is the division into aware and impaired awareness seizures; however, this is not applicable to neonates, as it is not possible to confidently and reproducibly assess awareness and responsiveness in this age group.

This is followed by the division into motor and non-motor seizures, and finally by the seizure type (Table 1). Although seizures in neonates can present with a variety of clinical signs, in the majority of cases a single *predominant* feature can be determined. Pragmatically, it appears best to classify seizures according to the predominant clinical manifestation, as this is more likely to have clinical implications for etiology than determination of the seizure-onset zone. This may or may not be the first clinical manifestation. For example, a neonate may present with focal tonic posturing, and in addition have some ocular myoclonus—this can still be classified as a tonic seizure. Regardless, as in adults, localization within the brain should be specified when known and appropriate.

In some situations, it may be difficult to identify the dominant feature, typically in longer seizures where a sequence of clinical features can be seen, often with changing lateralization. Events with a sequence of signs, symptoms, and EEG

changes at different times have been described as a sequential seizure in the 2017 ILAE classification manual.<sup>6</sup> Because this is often seen in neonates, this term was added to the seizure types. Sequential refers to several seizure manifestations occurring in sequence (not necessarily simultaneously) in a given seizure, and not manifestations in different seizure types (eg, a neonate may present with epileptic spasms and other focal seizures). Typical examples for sequential seizure are seen in neonates with self-limited neonatal epilepsy, which have been described as stereotyped with a variety of manifestations including tonic, clonic, automatisms, and autonomic features (including apnea), which show varying lateralization during a single seizure.<sup>54,55</sup> Similar seizures have been reported in neonates with *KCNQ2* or *SCN2A* encephalopathy.<sup>56–58</sup> Sequential seizures need to be differentiated from migrating focal seizures, which is an electroclinical phenomenon described in some genetic syndromes.<sup>59</sup>

Several seizure types described in the 2017 ILAE classification cannot be diagnosed in newborns due to lack of verbal and limited nonverbal communications. These include sensory, cognitive, and emotional seizures. Sensory seizures are defined as a perceptual experience not caused by appropriate stimuli in the external world. Such seizures may in rare cases produce semiology such as grimacing or crying, but it is assumed that in the vast majority of cases they would appear as electrographic-only events. Awareness and responsiveness cannot be accurately assessed in neonates and hence is not readily classified; however, this may change with more advanced technology or detailed observation. Similarly, somatosensory or visual auras cannot be determined in neonates. Due to the relatively low muscle tone and supine position of newborns, the occurrence of atonic seizures cannot be evaluated clinically without invasive methods.<sup>53</sup> These seizure types are therefore not included in the new classification. Motor seizures can be further described using descriptors as listed in Table 2. The framework allows the user to

classify the seizure in as much detail as required in a certain situation. The full description would include manifestation, a descriptor, and etiological diagnosis.

## 5.4 | Epilepsy syndromes

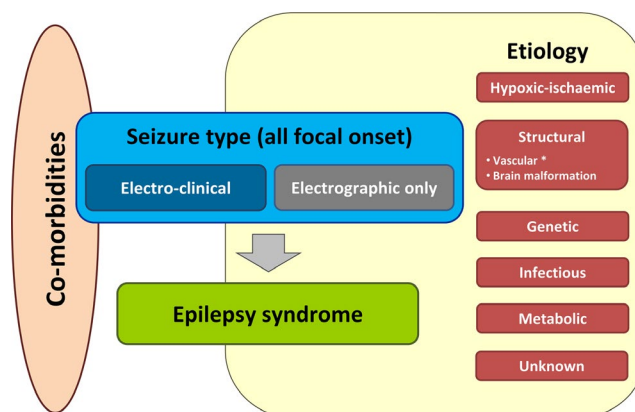
Although the majority of seizures in the neonatal period occur in the context of an acute illness, in some cases the seizures may be the first manifestation of early infantile epilepsy. Early differentiation of provoked seizures from neonatal-onset epilepsies has important diagnostic, therapeutic, and prognostic implications because the evaluation and long-term management of neonatal epilepsies are distinct from those of provoked seizures.<sup>60</sup> Syndromes presenting in the neonatal period include the following:<sup>61</sup> self-limited neonatal epilepsy (previously benign familial neonatal seizures) and early infantile developmental and epileptic encephalopathy (previously early myoclonic epilepsy and early infantile epileptic encephalopathy) (see also proposal by ILAE Task Force on Nosology and Definitions, in preparation).

Recent advances in neuroimaging and genomic technology as well as the implementation of video-EEG in the NICU, allow for the identification of more discrete, etiology-specific neonatal epilepsy syndromes than previously recognized.<sup>61–63</sup> It is likely that the combination of more sophisticated genetic testing and video-EEG monitoring will allow the identification and stratification of distinct etiology-specific electroclinical phenotypes,<sup>58</sup> as suggested in the new ILAE classification of the epilepsies.<sup>28</sup> This framework has been adapted for neonates (Figure 3).

## 6 | Discussion

In line with the new ILAE seizure classification<sup>7</sup> and ILAE framework for the epilepsies,<sup>28</sup> a new ILAE classification for seizures in the neonatal period has been developed by the ILAE neonatal task force. This classification emphasizes the role of EEG in the diagnosis of seizures and includes a classification of seizure types relevant to this age group. The seizure type is typically determined by the predominant clinical feature. In most electroclinical seizures in neonates, the first feature is also the predominant feature. Review of the literature suggests that seizure semiology in neonates may have diagnostic value with respect to etiology and/or outcome and thus implications for management (Table 1). For example, focal clonic movements can frequently be observed as the first and also predominant feature of seizures in perinatal stroke.

However, many of these clinical associations are based on small case studies or with very limited description of semiology and will need to be tested on a larger data set.



**FIGURE 3** Framework for neonatal seizures and epilepsy syndromes. Adapted from 2017 ILAE Framework of the epilepsies.<sup>28</sup> For the purpose of this paper, hypoxic-ischemic is considered a separate entity because it is the most common etiology of seizures in this age group. There is no evidence at present that immune processes play a role in seizure etiology in neonates. \*Including acute ischemic stroke, hemorrhage (intraventricular, subarachnoid, intraparenchymal), and other vascular induced ischemia (such as periventricular leukomalacia).

Clancy and colleagues described electrographic-only seizures in newborns as sudden, repetitive, evolving stereotyped waveforms with a definite beginning, middle, and end and a minimum duration of 10 s.<sup>46</sup> However, the choice of 10 s duration was explicitly arbitrary. Similarly, an arbitrary minimum duration of 10 s is also applied to the definition of a seizure in critically ill adults.<sup>64</sup> This is in contrast to some electroclinical seizures such as myoclonic seizures or spasms, which are by definition shorter than 10 s.<sup>6,7,65</sup> Both in neonates and critically ill adults it has been suggested that brief rhythmic discharges (so-called BRDs [brief rhythmic discharges] or BIRDs [brief interictal/ictal rhythmic discharges]) are associated with more sustained electrographic seizures with the same morphology in the same or subsequent EEG recording<sup>66–69</sup> and an increased risk of abnormal neurodevelopmental outcome.<sup>67</sup> BRDs are defined as very brief (<10 s) runs of focal or generalized sharply contoured rhythmic activity, with or without evolution, that are not consistent with any known normal or benign pattern, which in adults have a frequency greater than 4 Hz.<sup>70</sup>

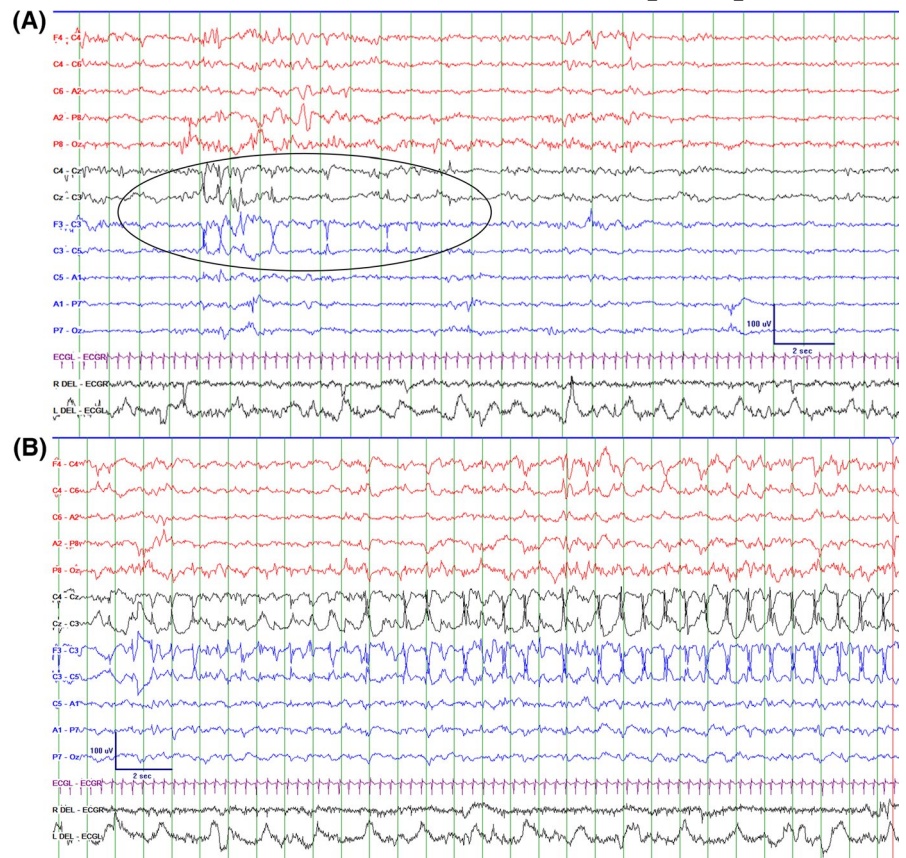
BRDs may be considered part of the ictal-interictal continuum. It is of interest that the presence or absence of evolution is not part of the definition. It has been suggested that definite BRDs with an evolution represent “very brief” electrographic seizures (Figure 4).<sup>69,70</sup>

We define seizures in the neonatal period as:

*An electrographic event with a pattern characterized by sudden, repetitive, evolving stereotyped waveforms with a beginning and end. The duration is not defined but has to be sufficient to demonstrate evolution in frequency and morphology of the discharges and needs to be long enough to*



**FIGURE 4** EEG in a term infant presenting on day 4 with seizures, illustrating the difficulties in the electrophysiological definition of seizures: (A) Initial EEG showed runs of rhythmic sharp waves with evolution in morphology and frequency over the mid to left central region (Cz/C3), here lasting 7 s (circled). This could be interpreted as a brief rhythmic discharge (BRD). (B) Subsequent prolonged EEG monitoring captured several electrographic-only seizures with a similar electrographic pattern over the same region, lasting up to 45 s. It is unclear why one should be considered a BRD, and the other an electrographic seizure.



*allow recognition of onset, evolution, and resolution of an abnormal discharge.*

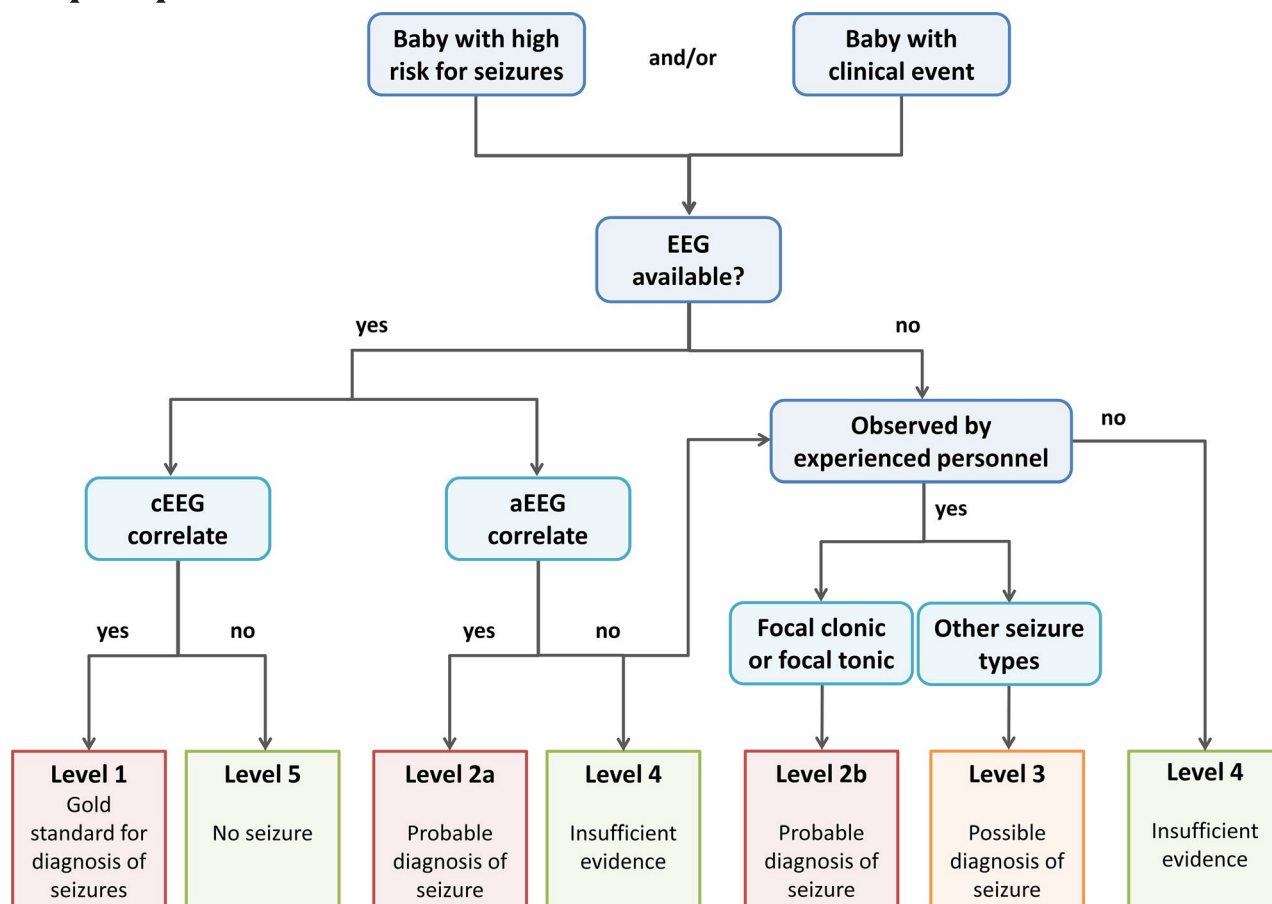
This is a conceptual definition and how this relates to decisions on therapy is discussed below. Although it has been suggested that 10 s may allow better interrater reliability, in some cases shorter ictal patterns may be identified as seizures because of their evolution and morphology similar to other events in the same recording that are longer and thus meet duration criterion. BRDs without evolution are not considered seizures but may serve as an early predictor of seizures during subsequent EEG monitoring and as a prognostic indicator. Notable exceptions are certain clinical seizures such as myoclonic seizures and spasms.

In defining electroclinical and electrographic-only seizures, we acknowledge that the decision of when to treat neonatal seizures depends not only on the correct diagnosis but just as much on the seizure burden. The seizure burden (electrographic seizure seconds in a given period), but not seizure frequency (number of seizures in a given period regardless of duration) or clinical manifestation, is associated with poor outcome.<sup>71</sup> It is generally agreed that rare brief seizures may not require treatment but should initiate EEG monitoring so that seizure burden can be evaluated.<sup>72</sup> It has been suggested that a seizure burden of >30–60 s per hour should be considered as an indication to start treatment.<sup>72</sup> Electrographic seizure burden and seizure frequency may impact the treatment approach, but the presence or absence

of clinical signs should not.<sup>25,26</sup> The ILAE Neonatal Seizure Guideline Task Force is currently updating the 2011 World Health Organization (WHO) guidelines for neonatal seizures,<sup>73</sup> which will be addressing these specific aspects of treatment related decision-making.

The task force accepts that the current reality in many regions of the world is that access to even the most basic EEG studies is not possible.<sup>4,74</sup> Acknowledging this, the role of the Task Force was to define the gold standard approach to diagnosis and recognition of neonatal seizures. This can be used to lobby for better facilities even if the process is challenging and takes many years to achieve.

If EEG is not available, we would like to refer to an algorithm developed by the Brighton collaboration defining different degrees of diagnostic certainties<sup>4</sup> depending on diagnostic tests available (Figure 5). EEG is regarded as the gold standard (definite diagnosis), whereas events seen on aEEG can be considered to be seizures with “probable certainty.” If only clinical evaluation is available, focal clonic seizures and focal tonic seizures can also be considered “probable seizures,” whereas other clinical events such as automatisms, autonomic seizures, and seizures with behavioral arrest would always require EEG confirmation and thus can be deemed “possible seizure,” only if no EEG is available. Electrographic-only seizures will, by definition, be missed without EEG. Generalized tonic extensor posturing events, without clear asymmetry, are



**FIGURE 5** Algorithm to determine degrees of diagnostic certainties for neonatal seizures. This flow chart will help to determine the diagnostic certainty of neonatal seizures depending on the available diagnostic method (EEG, aEEG or observation by experienced personnel) and seizure type. Developed by the Brighton collaboration (adapted from<sup>4</sup>). cEEG conventional EEG; aEEG; amplitude-integrated EEG

not considered seizures and bedside maneuvers can help in identifying clinical events as exaggerated reflex behaviors and nonepileptic in origin.<sup>9</sup> If stimulation of the infant provokes behaviors similar to a spontaneously observed clinical event suspected of being seizures and restraint of infant limbs during spontaneous events prompts an arrest of the events, they may be considered to be nonepileptic events. Although these infants may not have clinical seizures, the onset of these paroxysmal movements warrants further assessment, since they too can be associated with significant central nervous system disorders and subsequent neurological impairment.

This position paper does not address the definition or classification of status epilepticus in neonates. Neonatal status epilepticus is relatively common and is associated with poor outcome but no widely accepted definition exists.<sup>75</sup> The recent report of the ILAE task force of status epilepticus<sup>76</sup> is only partially applicable to neonates, as it does not address seizure burden and electrographic-only seizures and does not take into account that status epilepticus-induced hippocampal injury is age dependent and less likely to occur in the young.<sup>77</sup>

Although this framework was developed for seizures in the neonatal period, we believe that some aspects can be readily applied to acute seizures in critically ill patients of any age, particularly within the intensive care setting. Nonconvulsive seizures are common in critically ill patients<sup>78</sup> and electrographic-only presentation due to electroclinical uncoupling has been described in two thirds of critically ill children with seizures.<sup>79,80</sup> However, the etiologies may vary with age. Further prospective evaluations of this classification are recommended in neonates.

#### ACKNOWLEDGMENTS

Special thanks are given to all members of the ILAE and other stakeholders who have contributed to the public comments; their contribution to finalizing this classification was invaluable. Additional helpful key comments were received from the International Federation of Clinical Neurophysiology (an ad hoc group led by Dr Monika Eisermann, Paris).

#### CONFLICT OF INTEREST

Ronit M. Pressler has no conflicts of interest in regards to this article. She is an investigator for studies with UCB

and Johnson & Johnson. She served as a Consultant and on Advisory Boards for Eisai and UCB. Her research is supported by the National Institute of Health Research (NIHR) Biomedical Research Centre at Great Ormond Street Hospital, Cambridge Biomedical Research Centre, NIHR and GOSH Charity. Solomon L. Moshé has no conflicts of interest in regards to this article. He is the Charles Frost Chair in Neurosurgery and Neurology and partially funded by grants from National Institutes of Health (NIH) U54 NS100064 and NS43209, US Department of Defense (W81XWH-13-1-0180 and EP170020), CURE Infantile Spasms Initiative, and the Heffer Family and the Segal Family Foundations and the Abbe Goldstein/Joshua Lurie and Laurie Marsh/Dan Levitz families. He is serving as Associate Editor of *Neurobiology of Disease* and is on the editorial board of *Brain and Development*, *Pediatric Neurology and Physiological Research*. He receives from Elsevier an annual compensation for his work as Associate Editor of *Neurobiology of Disease* and royalties from two books he co-edited. He received a consultant fee from Eisai, Mallinckrodt, Pfizer, and UCB. Eli M. Mizrahi has no conflicts of interest with regard to this article. He has received consultant fees from Eisai and royalties from Elsevier, McGraw-Hill and Springer publishers. Sameer M. Zuberi has no conflicts of interest in relation to this article. He has received research funding from Epilepsy Research UK, UCB Pharma, Dravet Syndrome UK, and Glasgow Childrens Hospital Charity. He has served as a Consultant and on Advisory Boards for Encoded Genomics, Zogenix, UCB Pharma, Biocodex. He receives an honorarium from Elsevier for his role as Editor-in-Chief of the *European Journal of Paediatric Neurology*. Jo M. Wilmschurst has no conflicts of interest in regard to this article. She has received a stipend from Wiley for her role as an Associate Editor for *Epilepsia*. Magda L. Nunes has no conflicts of interest in regards to this article. She is a researcher ID supported by CNPq-Brazil, PQ grant number 306338/2017-3. Sampsa Vanhatalo has no conflicts of interest in regards to this article. He is supported by the Finnish Academy (SV: 313242, 288220, 3104450), Pediatric foundation, and HUS Children's Hospital. Maria Roberta Cilio has no conflict of interest in regards to this article. She served as Consultant and on Advisory Boards for GW Pharmaceuticals, UCB, Sanofi Pharma, and Biocodex. She receives royalties from Elsevier as co-editor of a book. The other authors have no conflict of interest to disclose in relation to this publication. We confirm that we have read the Journal's position on issues involved in ethical publication and affirm that this report is consistent with those guidelines.

#### ETHICAL PUBLICATION STATEMENT

We confirm that we have read the Journal's position on issues involved in ethical publication and affirm that this report is consistent with those guidelines.

#### ORCID

Ronit M. Pressler  <https://orcid.org/0000-0002-2905-6839>  
 Maria Roberta Cilio  <https://orcid.org/0000-0003-2481-8053>  
 Solomon L. Moshé  <https://orcid.org/0000-0001-9427-9476>  
 Magda L. Nunes  <https://orcid.org/0000-0002-3402-6810>  
 Elissa Yozawitz  <https://orcid.org/0000-0001-8230-8364>  
 Jo M. Wilmschurst  <https://orcid.org/0000-0001-7328-1796>

#### REFERENCES

- Engle WA. Age terminology during the perinatal period. *Pediatrics*. 2004;114(5):1362–4.
- WHO. Preterm birth, fact sheet, 2016.
- Lanska MJ, Lanska DJ, Baumann RJ, Kryscio RJ. A population-based study of neonatal seizures in Fayette County, Kentucky. *Neurology*. 1995;45(4):724–32.
- Pellegrin S, Munoz FM, Padula M, Heath PT, Meller L, Top K, et al. Neonatal seizures: Case definition & guidelines for data collection, analysis, and presentation of immunization safety data. *Vaccine*. 2019;37(52):7596–609.
- Ronen GM, Penney S, Andrews W. The epidemiology of clinical neonatal seizures in Newfoundland: a population-based study. *J Pediatr*. 1999;134(1):71–5.
- Fisher RS, Cross JH, D'Souza C, French JA, Haut SR, Higurashi N, et al. Instruction manual for the ILAE 2017 operational classification of seizure types. *Epilepsia*. 2017;58(4):531–42.
- Fisher RS, Cross JH, French JA, Higurashi N, Hirsch E, Jansen FE, et al. Operational classification of seizure types by the International League Against Epilepsy: Position Paper of the ILAE Commission for Classification and Terminology. *Epilepsia*. 2017;58(4):522–30.
- Glass HC, Shellhaas RA, Wusthoff CJ, Chang T, Abend NS, Chu CJ, et al. Contemporary profile of seizures in neonates: a prospective cohort study. *J Pediatr*. 2016;174:98–103.e1.
- Mizrahi EM, Kellaway P. Characterization and classification of neonatal seizures. *Neurology*. 1987;37(12):1837–44.
- Scher MS, Alvin J, Gaus L, Minnigh B, Painter MJ. Uncoupling of EEG-clinical neonatal seizures after antiepileptic drug use. *Pediatr Neurol*. 2003;28(4):277–80.
- Nash KB, Bonifacio SL, Glass HC, Sullivan JE, Barkovich AJ, Ferriero DM, et al. Video-EEG monitoring in newborns with hypoxic-ischemic encephalopathy treated with hypothermia. *Neurology*. 2011;76(6):556–62.
- Malone A, Ryan CA, Fitzgerald A, Burgoyne L, Connolly S, Boylan GB. Interobserver agreement in neonatal seizure identification. *Epilepsia*. 2009;50(9):2097–101.
- Galanopoulou AS, Moshe SL. In search of epilepsy biomarkers in the immature brain: goals, challenges and strategies. *Biomarkers Med*. 2011;5(5):615–28.
- Haut SR, Veliskova J, Moshe SL. Susceptibility of immature and adult brains to seizure effects. *Lancet Neurol*. 2004;3(10):608–17.
- Murray DM, Boylan GB, Ali I, Ryan CA, Murphy BP, Connolly S. Defining the gap between electrographic seizure burden, clinical expression and staff recognition of neonatal seizures. *Arch Dis Child Fetal Neonatal Ed*. 2008;93(3):F187–F191.
- Boylan GB, Pressler RM, Pressler RM, Rennie JM, Morton M, Leow PL, et al. Outcome of electroclinical, electrographic, and



- clinical seizures in the newborn infant. *Dev Med Child Neurol*. 1999;41(12):819–25.
17. Boylan GB, Rennie JM, Pressler RM, Wilson G, Morton M, Binnie CD. Phenobarbitone, neonatal seizures, and video-EEG. *Arch Dis Child Fetal Neonatal Ed*. 2002;86(3):F165–F170.
  18. Shellhaas RA, Chang T, Tsuchida T, Scher MS, Riviello JJ, Abend NS, et al. The American clinical neurophysiology society's guideline on continuous electroencephalography monitoring in neonates. *J Clin Neurophysiol*. 2011;28(6):611–7.
  19. Hahn CD, Riviello JJ. Neonatal Seizures and EEG. *NeoReviews*. 2004;5(8):e350–e355.
  20. Mathieson SR, Livingstone V, Low E, Pressler R, Rennie JM, Boylan GB. Phenobarbital reduces EEG amplitude and propagation of neonatal seizures but does not alter performance of automated seizure detection. *Clin Neurophysiol*. 2016;127(10):3343–50.
  21. Weiner SP, Painter MJ, Geva D, Guthrie RD, Scher MS. Neonatal seizures: electroclinical dissociation. *Pediatr Neurol*. 1991;7(5):363–8.
  22. Kharoshankaya L, Stevenson NJ, Livingstone V, Murray DM, Murphy BP, Ahearne CE, et al. Seizure burden and neurodevelopmental outcome in neonates with hypoxic-ischemic encephalopathy. *Dev Med Child Neurol*. 2016;58(12):1242–8.
  23. McBride MC, Laroia N, Guillet R. Electrographic seizures in neonates correlate with poor neurodevelopmental outcome. *Neurology*. 2000;55(4):506–13.
  24. Miller SP, Weiss J, Barnwell A, Ferriero DM, Latal-Hajnal B, Ferrer-Rogers A, et al. Seizure-associated brain injury in term newborns with perinatal asphyxia. *Neurology*. 2002;58(4):542–8.
  25. Srinivasakumar P, Zempel J, Trivedi S, Wallendorf M, Rao R, Smith B, et al. Treating EEG seizures in hypoxic ischemic encephalopathy: a randomized controlled trial. *Pediatrics*. 2015;136(5):e1302–e1309.
  26. van Rooij LGM, Toet MC, van Huffelen AC, Groenendaal F, Laan W, Zecic A, et al. Effect of treatment of subclinical neonatal seizures detected with aEEG: randomized, controlled trial. *Pediatrics*. 2010;125(2):e358–e366.
  27. Tsuchida TN, Wusthoff CJ, Shellhaas RA, Abend NS, Hahn CD, Sullivan JE, et al. American clinical neurophysiology society standardized EEG terminology and categorization for the description of continuous EEG monitoring in neonates: report of the american clinical neurophysiology society critical care monitoring committee. *J Clin Neurophysiol*. 2013;30(2):161–73.
  28. Scheffer IE, Berkovic S, Capovilla G, Connolly MB, French J, Guilhoto L, et al. ILAE classification of the epilepsies: Position paper of the ILAE Commission for Classification and Terminology. *Epilepsia*. 2017;58(4):512–21.
  29. Burke JB. The prognostic significance of neonatal convulsions. *Arch Dis Child*. 1954;29(146):342–5.
  30. Dreyfus-Brisac C, Monod N. Electroclinical studies of status epilepticus and convulsions in the newborn. In: Kellaway P, Hrachovy RA, editors. *Neurological and Electroencephalographic Correlative Studies in Infancy*. New York: Grune and Statton; 1964. p. 250–72.
  31. Harris R, Tizard JP. The electroencephalogram in neonatal convulsions. *J Pediatr*. 1960;57:501–20.
  32. Rose AL, Lombroso CT. A study of clinical, pathological, and electroencephalographic features in 137 full-term babies with a long-term follow-up. *Pediatrics*. 1970;45(3):404–25.
  33. Schulte FJ. Neonatal convulsions and their relation to epilepsy in early childhood. *Dev Med Child Neurol*. 1966;8(4):381–92.
  34. Minkowski A, Ste Anne-Dargassies S, Dreyfus-Brisac C, Samson D. Convulsive state in the newborn infant. *Arch francaises de Pediatr*. 1955;12(3):271–84.
  35. Lombroso CT. Seizures in the newborn. In: Vinken PJ, Bruyn GW, editors. *The Epilepsies Handbook of Clinical Neurology*, vol. 15. Amsterdam: North Holland; 1974. p. 189–218.
  36. Volpe JJ. Neonatal seizures. *Clin Perinatol*. 1977;4(1):43–63.
  37. Volpe JJ. Neonatal seizures: current concepts and revised classification. *Pediatrics*. 1989;84(3):422–8.
  38. Mizrahi EM, Pressler RM. Foundations of neonatal epileptology: classification of seizures and epilepsies in the neonate and their aetiology, electroencephalography, prognosis and pathophysiology. In: Moshé SL, Cross JH, de Bellescize J, de Vries L, Nordli D, Vigevano F, editors. *Seizures and Syndromes of Onset in the First Two Years of Life*. Paris: John Libbey; 2015.
  39. Germano IM, Sperber EF, Ahuja S, Moshe SL. Evidence of enhanced kindling and hippocampal neuronal injury in immature rats with neuronal migration disorders. *Epilepsia*. 1998;39(12):1253–60.
  40. Lawrence R, Indera TE, Mathur AM. Developing clinical trials for the diagnosis and treatment of neonatal seizures. *J Pediatr Neurol*. 2009;7(1):69–77.
  41. Plouin P, Kaminska A. Neonatal seizures. *Handb Clin Neurol*. 2013;111:467–76.
  42. Silverstein FS, Jensen FE, Inder T, Hellstrom-Westas L, Hirtz D, Ferriero DM. Improving the treatment of neonatal seizures: National Institute of Neurological Disorders and Stroke Workshop Report. *J Pediatr*. 2008;153(1):12–5.e1.
  43. Shellhaas RA, Soaita AI, Clancy RR. Sensitivity of amplitude-integrated electroencephalography for neonatal seizure detection. *Pediatrics*. 2007;120(4):770–7.
  44. Van Rooij LGM, De Vries LS, Van Huffelen AC, Toet MC. Additional value of two-channel amplitude integrated EEG recording in full-term infants with unilateral brain injury. *Arch Dis Child Fetal Neonatal Ed*. 2010;95(3):F160–F168.
  45. Rakshasbhuvarkar A, Paul S, Nagarajan L, Ghosh S, Rao S. Amplitude-integrated EEG for detection of neonatal seizures: a systematic review. *Seizure*. 2015;33:90–8.
  46. Clancy RR, Legido A, Lewis D. Occult neonatal seizures. *Epilepsia*. 1988;29(3):256–61.
  47. Worden LT, Chinappen DM, Stoyell SM, Gold J, Paixao L, Krishnamoorthy K, et al. The probability of seizures during continuous EEG monitoring in high-risk neonates. *Epilepsia*. 2019;60(12):2508–18.
  48. Facini C, Spagnoli C, Pisani F. Epileptic and non-epileptic paroxysmal motor phenomena in newborns. *J Matern Fetal Neonatal Med*. 2016;29(22):3652–9.
  49. Scher MS. Controversies regarding neonatal seizure recognition. *Epileptic Disord*. 2002;4(2):139–58.
  50. From the Commission on Classification and Terminology of the International League Against Epilepsy. Proposal for revised clinical and electroencephalographic classification of epileptic seizures. *Epilepsia*. 1981;22(4):489–501.
  51. Engel J Jr. Report of the ILAE classification core group. *Epilepsia*. 2006;47(9):1558–68.
  52. Nagarajan L, Ghosh S, Palumbo L. Ictal electroencephalograms in neonatal seizures: characteristics and associations. *Pediatr Neurol*. 2011;45(1):11–6.

53. Nagarajan L, Palumbo L, Ghosh S. Classification of clinical semiology in epileptic seizures in neonates. *Eur J Paediatr Neurol*. 2012;16(2):118–25.
54. Hirsch E, Velez A, Sella F, Maton B, Grinspan A, Malafosse A, et al. Electroclinical signs of benign neonatal familial convulsions. *Ann Neurol*. 1993;34(6):835–41.
55. Sands TT, Balestri M, Bellini G, Mulkey SB, Danhaive O, Bakken EH, et al. Rapid and safe response to low-dose carbamazepine in neonatal epilepsy. *Epilepsia*. 2016;57(12):2019–30.
56. Milh M, Boutry-Kryza N, Sutura-Sardo J, Mignot C, Auvin S, Lacoste C, et al. Similar early characteristics but variable neurological outcome of patients with a de novo mutation of KCNQ2. *Orphanet J Rare Dis*. 2013;8:80.
57. Weckhuysen S, Ivanovic V, Hendrickx R, Van Coster R, Hjalgrim H, Moller RS, et al. Extending the KCNQ2 encephalopathy spectrum: clinical and neuroimaging findings in 17 patients. *Neurology*. 2013;81(19):1697–703.
58. Zara F, Specchio N, Striano P, Robbiano A, Gennaro E, Paravidino R, et al. Genetic testing in benign familial epilepsies of the first year of life: clinical and diagnostic significance. *Epilepsia*. 2013;54(3):425–36.
59. McTague A, Appleton R, Avula S, Cross JH, King MD, Jacques TS, et al. Migrating partial seizures of infancy: expansion of the electroclinical, radiological and pathological disease spectrum. *Brain*. 2013;136(Pt 5):1578–91.
60. Shellhaas RA, Wusthoff CJ, Tsuchida TN, Glass HC, Chu CJ, Massey SL, et al. Profile of neonatal epilepsies: characteristics of a prospective US cohort. *Neurology*. 2017;89(9):893–9.
61. ILAE. *EpilepsyDiagnosis.org*. last updated 2020.
62. Olson HE, Kelly McKenna, LaCoursiere CM, Pinsky R, Tambunan D, Shain C, et al. Genetics and genotype-phenotype correlations in early onset epileptic encephalopathy with burst suppression. *Ann Neurol*. 2017;81(3):419–29.
63. Cornet MC, Sands TT, Cilio MR. Neonatal epilepsies: clinical management. *Semin Fetal Neonatal Med*. 2018;23(3):204–12.
64. Chong DJ, Hirsch LJ. Which EEG patterns warrant treatment in the critically ill? Reviewing the evidence for treatment of periodic epileptiform discharges and related patterns. *J Clin Neurophysiol*. 2005;22(2):79–91.
65. Blume WT, Lüders HO, Mizrahi E, Tassinari C, van Emde BW, Engel J Jr. Glossary of descriptive terminology for ictal semiology: report of the ILAE task force on classification and terminology. *Epilepsia*. 2001;42(9):1212–8.
66. Nagarajan L, Palumbo L, Ghosh S. Brief electroencephalography rhythmic discharges (BERDs) in the neonate with seizures: their significance and prognostic implications. *J Child Neurol*. 2011;26(12):1529–33.
67. Oliveira AJ, Nunes ML, Haertel LM, Reis FM, da Costa JC. Duration of rhythmic EEG patterns in neonates: new evidence for clinical and prognostic significance of brief rhythmic discharges. *Clin Neurophysiol*. 2000;111(9):1646–53.
68. Shewmon DA. What is a neonatal seizure? Problems in definition and quantification for investigative and clinical purposes. *J Clin Neurophysiol*. 1990;7(3):315–68.
69. Yoo JY, Rampal N, Petroff OA, Hirsch LJ, Gaspard N. Brief potentially ictal rhythmic discharges in critically ill adults. *JAMA Neurol*. 2014;71(4):454–62.
70. Yoo JY, Marcuse LV, Fields MC, Rosengard JL, Traversa MV, Gaspard N, et al. Brief potentially ictal rhythmic discharges [B(I)RDs] in noncritically ill adults. *J Clin Neurophysiol*. 2017;34(3):222–9.
71. Pinchevsky EF, Hahn CD. Outcomes following electrographic seizures and electrographic status epilepticus in the pediatric and neonatal ICUs. *Curr Opin Neurol*. 2017;30(2):156–64.
72. Soul JS, Pressler R, Allen M, Boylan G, Rabe H, Portman R, et al. Recommendations for the design of therapeutic trials for neonatal seizures. *Pediatr Res*. 2019;85(7):943–54.
73. WHO. Guidelines on Neonatal Seizures. Geneva: World Health Organization; 2011.
74. Co JPT, Elia M, Engel J, Guerrini R, Mizrahi EM, Moshé SL, et al. Proposal of an algorithm for diagnosis and treatment of neonatal seizures in developing countries. *Epilepsia*. 2007;48(6):1158–64.
75. Abend NS, Wusthoff CJ. Neonatal seizures and status epilepticus. *J Clin Neurophysiol*. 2012;29(5):441–8.
76. Trinka E, Cock H, Hesdorffer D, Rossetti AO, Scheffer IE, Shinnar S, et al. A definition and classification of status epilepticus—Report of the ILAE Task Force on Classification of Status Epilepticus. *Epilepsia*. 2015;56(10):1515–23.
77. Molinero I, Galanopoulou AS, Moshé SL. Rodent models: Where it all started with these "truths". *Eur J Paediatr Neurol*. 2020;24:61–5.
78. Claassen J, Mayer SA, Kowalski RG, Emerson RG, Hirsch LJ. Detection of electrographic seizures with continuous EEG monitoring in critically ill patients. *Neurology*. 2004;62(10):1743–8.
79. Abend NS, Gutierrez-Colina AM, Topjian AA, Zhao H, Guo R, Donnelly M, et al. Nonconvulsive seizures are common in critically ill children. *Neurology*. 2011;76(12):1071–7.
80. Schreiber JM, Zelleke T, Gaillard WD, Kaulas H, Dean N, Carpenter JL. Continuous video EEG for patients with acute encephalopathy in a pediatric intensive care unit. *Neurocrit Care*. 2012;17(1):31–8.
81. Janáčková S, Boyd S, Yozawitz E, Tsuchida T, Lamblin M-D, Gueden S, et al. Electroencephalographic characteristics of epileptic seizures in preterm neonates. *Clin Neurophysiol*. 2016;127(8):2721–7.
82. Weeke LC, Groenendaal F, Toet MC, Benders MJNL, Nivelstein RAJ, van Rooij LGM, et al. The aetiology of neonatal seizures and the diagnostic contribution of neonatal cerebral magnetic resonance imaging. *Dev. Med. Child Neurol*. 2015;57(3):248–56.
83. Ronen GM, Rosales TO, Connolly M, Anderson VE, Leppert M. Seizure characteristics in chromosome 20 benign familial neonatal convulsions. *Neurology*. 1993;43(7):1355–60.
84. Vecchi M, Suppiej A, Mastrangelo M, Boniver C. Focal motor seizure with automatisms in a newborn. *Epileptic Disord*. 2007;9(2):149–52.
85. Low E, Mathieson SR, Stevenson NJ, Livingstone V, Ryan CA, Bogue CO, et al. Early postnatal EEG features of perinatal arterial ischaemic stroke with seizures. *PLoS One*. 2014;9(7):e100973.
86. Nunes ML, Martins MP, Barea BM, Wainberg RC, Costa JC. Neurological outcome of newborns with neonatal seizures: a cohort study in a tertiary university hospital. *Arq Neuropsiquiatr*. 2008;66(2a):168–74.
87. Schulzke S, Weber P, Luetsch J, Fahnenstich H. Incidence and diagnosis of unilateral arterial cerebral infarction in newborn infants. *J Perinat Med*. 2005;33(2):170–5.



88. Ohtahara S, Yamatogi Y. Ohtahara syndrome: with special reference to its developmental aspects for differentiating from early myoclonic encephalopathy. *Epilepsy Res.* 2006;70(Suppl 1):S58–67.
89. Beniczky S, Conradsen I, Pressler R, Wolf P. Quantitative analysis of surface electromyography: biomarkers for convulsive seizures. *Clin Neurophysiol.* 2016;127(8):2900–7.
90. Kobayashi K, Inoue T, Kikumoto K, Endoh F, Miya K, Oka M, et al. Relation of spasms and myoclonus to suppression-burst on EEG in epileptic encephalopathy in early infancy. *Neuropediatrics.* 2007;38(5):244–50.
91. Watanabe K, Miura K, Natsume J, Hayakawa F, Furune S, Okumura A. Epilepsies of neonatal onset: seizure type and evolution. *Dev Med Child Neurol.* 1999;41(5):318–22.
92. Cusmai R, Martinelli D, Moavero R, Dionisi Vici C, Vigeveno F, Castana C, et al. Ketogenic diet in early myoclonic encephalopathy due to non ketotic hyperglycinemia. *Eur J Paediatr Neurol.* 2012;16(5):509–13.
93. Dalla Bernardina B, Aicardi J, Goutières F, Plouin P. Glycine encephalopathy. *Neuropediatrics.* 1979;10(3):209–25.
94. Djukic A, Lado FA, Shinnar S, Moshé SL. Are early myoclonic encephalopathy (EME) and the Ohtahara syndrome (EIEE) independent of each other? *Epilepsy Res.* 2006;70(Suppl 1):S68–76.
95. Porri S, Fluss J, Plecko B, Paschke E, Korff CM, Kern I. Positive outcome following early diagnosis and treatment of pyridoxal-5'-phosphate oxidase deficiency: a case report. *Neuropediatrics.* 2014;45(1):64–8.
96. Milh M, Villeneuve N, Chouchane M, Kaminska A, Laroche C, Barthez MA, et al. Epileptic and nonepileptic features in patients with early onset epileptic encephalopathy and STXBP1 mutations. *Epilepsia.* 2011;52(10):1828–34.
97. Mulkey SB, Ben-Zeev B, Nicolai J, Carroll JL, Grønberg S, Jiang YH, et al. Neonatal nonepileptic myoclonus is a prominent clinical feature of KCNQ2 gain-of-function variants R201C and R201H. *Epilepsia.* 2017;58(3):436–45.
98. Numis AL, Angriman M, Sullivan JE, Lewis AJ, Striano P, Nabbut R, et al. KCNQ2 encephalopathy: delineation of the electroclinical phenotype and treatment response. *Neurology.* 2014;82(4):368–70.
99. Weckhuysen S, Mandelstam S, Suls A, Audenaert D, Deconinck T, Claes LRF, et al. KCNQ2 encephalopathy: emerging phenotype of a neonatal epileptic encephalopathy. *Ann Neurol.* 2012;71(1):15–25.
100. Wolff M, Brunklaus A, Zuberi SM. Phenotypic spectrum and genetics of SCN2A-related disorders, treatment options, and outcomes in epilepsy and beyond. *Epilepsia.* 2019;60(Suppl 3):S59–s67.
101. Kato M, Yamagata T, Kubota M, Arai H, Yamashita S, Nakagawa T, et al. Clinical spectrum of early onset epileptic encephalopathies caused by KCNQ2 mutation. *Epilepsia.* 2013;54(7):1282–7.
102. Castro Conde JR, Gonzalez-Hernandez T, Gonzalez Barrios D, Gonzalez CC. Neonatal apneic seizure of occipital lobe origin: continuous video-EEG recording. *Pediatrics.* 2012;129(6):e1616–e1620.
103. Sirsi D, Nadiminti L, Packard MA, Engel M, Solomon GE. Apneic seizures: a sign of temporal lobe hemorrhage in full-term neonates. *Pediatr Neurol.* 2007;37(5):366–70.
104. Vigeveno F, de Liso P, Bureau M, Plouin P, Neubauer BA, Trivisano M, et al. Benign neonatal and infantile seizures and epilepsies. In: Bureau M, Genton P, Dravet C, editors. *Epileptic Syndromes in Infancy, Childhood and Adolescence*, 6th edn. Paris: John Libbey; 2019. p. 79–90.
105. Nunes ML, Yozawitz EG, Zuberi S, Mizrahi EM, Cilio MR, Moshé SL, et al. Neonatal seizures: Is there a relationship between ictal electroclinical features and etiology? A critical appraisal based on a systematic literature review. *Epilepsia Open.* 2019;4(1):10–29.
106. Glass HC, Shellhaas RA, Tsuchida TN, Chang T, Wusthoff CJ, Chu CJ, et al. Seizures in preterm neonates: a multicenter observational cohort study. *Pediatr Neurol.* 2017;72:19–24.
107. Naim MY, Gaynor JW, Chen J, Nicolson SC, Fuller S, Spray TL, et al. Subclinical seizures identified by postoperative electroencephalographic monitoring are common after neonatal cardiac surgery. *J Thorac Cardiovasc Surg.* 2015;150(1):169–80.
108. Scher MS, Aso K, Beggarly ME, Hamid MY, Steppe DA, Painter MJ. Electrographic seizures in preterm and full-term neonates: clinical correlates, associated brain lesions, and risk for neurologic sequelae. *Pediatrics.* 1993;91(1):128–34.
109. Vesoulis ZA, Inder TE, Woodward LJ, Buse B, Vavasseur C, Mathur AM. Early electrographic seizures, brain injury, and neurodevelopmental risk in the very preterm infant. *Pediatr Res.* 2014;75(4):564–9.

## SUPPORTING INFORMATION

Additional supporting information may be found online in the Supporting Information section.

**How to cite this article:** Pressler RM, Cilio MR, Mizrahi EM, et al. The ILAE classification of seizures and the epilepsies: Modification for seizures in the neonate. Position paper by the ILAE Task Force on Neonatal Seizures. *Epilepsia.* 2021;62:615–628. <https://doi.org/10.1111/epi.16815>